

## REVIEW ARTICLE

Ichthyosis: A Road Model for Skin Research<sup>1</sup>

Anders VAHLQUIST and Hans TÖRMÄ

Department of Medical Sciences, Uppsala University, Uppsala, Sweden

**The understanding of monogenetic disorders of cornification, including the group of diseases called ichthyoses, has expanded greatly in recent years. Studies of the aetiology of more than 50 types of ichthyosis have almost invariably uncovered errors in the biosynthesis of epidermal lipids or structural proteins essential for normal skin barrier function. The barrier abnormality *per se* may elicit epidermal inflammation, hyperproliferation and hyperkeratosis, potentially contributing to the patient's skin symptoms. Despite this and other new knowledge about pathomechanisms, treatment of ichthyosis often remains unsatisfactory. This review highlights a series of approaches used to elucidate the pathobiology and clinical consequences of different types of ichthyosis, and related diseases with the ultimate goal of finding new and better treatments.**

**Key words:** skin pH; ARCI; human epidermis; keratins; ceramides; therapy; epidermolytic; congenital; keratinocytes.

Accepted Feb 12, 2020; Epub ahead of print Mar 9, 2020

Acta Derm Venereol 2020; 100: adv00097.

**Corr:** Anders Vahlquist and Hans Törmä, Department of Medical Sciences, Uppsala University, SE-751 85 Uppsala, Sweden. E-mails: anders.vahlquist@medsci.uu.se, hans.torma@medsci.uu.se

Ichthyosis is an umbrella term for more than 50 types of, usually monogenetic, diseases, all characterized by widespread hyperkeratosis, xerosis and scaling of the skin, sometimes also associated with syndromic features. Typically, the skin problems begin at birth or shortly thereafter and usually show lifelong persistence. Depending on the underlying genotype, disease intensity ranges from mild to severe, in the latter case markedly reducing the patients' quality of life (1). Only rarely are there life-threatening consequences; for example, in neonates with harlequin ichthyosis (HI), epidermolytic ichthyosis (EI) and certain types of syndromic ichthyosis (2, 3). Later in life, less severe, but more common, complications occur, such as pruritus, ectropion and anhidrosis (Fig. S1<sup>2</sup>). Careful medical attention is frequently required, including oral retinoid therapy. Yet, the vast majority of patients with ichthyosis have only mild to moderate

## SIGNIFICANCE

Ichthyosis refers to skin diseases with scaling somewhat reminiscent of fish scales (Greek: *ichthus*=fish). There are more than 50 genetic types of, mostly non-syndromic, ichthyosis, ranging in severity and frequency from mild and common (prevalence < 1%) to severe and rare (< 0.001%). In the latter case, babies are often born with a thick horny layer (collodion), dermal inflammation and impaired skin barrier function, requiring intensive medical care. Nearly all patients with ichthyosis require daily applications of cream, sometimes complemented with retinoid tablets. This review highlights recent progress in the understanding of the causes and consequences of ichthyosis, which may lead to better care and treatments.

skin symptoms, which are readily controlled by daily applications of cream (2, 3).

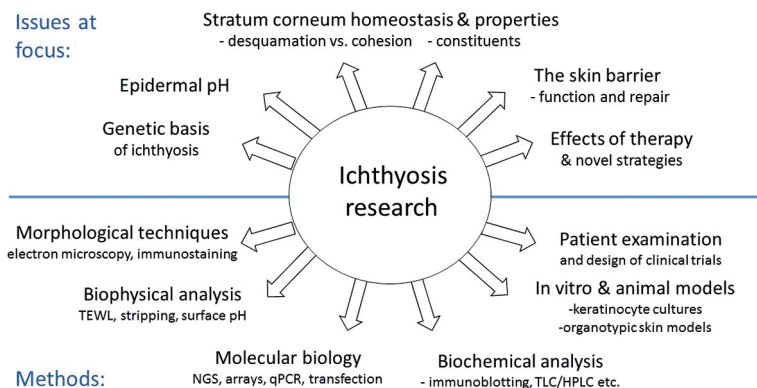
Despite a thick stratum corneum (SC), patients with ichthyosis usually have variably increased transepidermal water loss (TEWL). This is due to various defects in the biosynthesis of proteins and lipids essential for normal barrier formation, specific for each of the 4 main types of non-syndromic ichthyosis (4):

- *Ichthyosis vulgaris* (I. vulgaris; prevalence 1:300) due to semi-dominant *FLG* mutations abolishing filaggrin's compaction of keratin filaments and release of hydrophilic molecules in the corneocytes.
- *X-linked recessive ichthyosis* (XRI; 1:3000 in males) caused by a deficiency of steroid sulphatase, resulting in accumulation of cholesterol sulphate (CSO<sub>4</sub>) in the SC.
- *Autosomal recessive congenital ichthyosis* (ARCI; prevalence 1:100,000, including HI) due to mutations in any of >10 genes involved in the biosynthesis of acylceramides (acylCer), lipid lamellae and cornified lipid envelopes (CLE).
- *Keratinopathic ichthyosis* (1:300,000, including EI) caused by dominant negative mutations in keratin 1, 2 or 10, impairing the structural integrity of terminally differentiated keratinocytes.

This overview exemplifies a wide range of approaches used to elucidate the aetiopathogenesis of various types of ichthyosis, research that concurrently results in a better understanding of normal human skin biology and yields new ideas about dermatotherapy (Fig. 1).

<sup>1</sup>This article is based partly on the Dohi Memorial Lecture presented at the 118<sup>th</sup> Annual Meeting of the Japanese Dermatological Association in Nagoya, June 2019.

<sup>2</sup><https://www.medicaljournals.se/acta/content/abstract/10.2340/00015555-3433>



**Fig. 1. Examples of scientific issues and methodological approaches in ichthyosis research.** NGS: next generation sequencing; LC: liquid chromatography.

## MICROSCOPIC EXPLORATION OF ICHTHYOSIS

The ingenious construction of human epidermis, with its many disparate functions and constant renewal of cells, also makes it vulnerable to genetic defects, frequently causing clearcut structural abnormalities. Thus, under light microscopy, *I. vulgaris* displays an absence of stratum granulosum (below SC) and in EI and ichthyosis with confetti due to various keratin mutations a clumping of intermediate filaments is seen, occasionally leading to cytolysis of suprabasal keratinocytes. However, in most other types of ichthyosis, electron microscopy (EM) is required to disclose the histopathological hallmarks (5–11).

In ARCI, for example, 4 distinctive ultrastructural patterns are identifiable in the granular and corneal layers of the epidermis: EM type 1 (lipid droplets), probably related to epidermal hyperproliferation (5); EM type 2 (“cholesterol clefts” (6)), typically associated with *TGM1* mutations (12); EM type 3 (abnormal lamellar bodies and elongated membranes (7)), often associated with *NIPAL4* mutations (9); and, EM type 4 (aggregated lipid membranes), exclusively associated with *SCL27A4* mutations (13, 14). Furthermore, HI and related conditions due to *ABCA12* mutations often show prominent distortions of the lamellar bodies (11, 15). Finally, and common to most types of ARCI, the lipid bilayers and CLEs are attenuated, best seen after ruthenium staining of the skin specimen (10).

EM analysis is clinically useful for differentiating ARCI from other conditions. For example, in a diagnostic team effort 2 Scandinavian half-brothers, initially believed to have an atypical form of ARCI, showed no signs of EM types 1–4, but the corneodesmosomes were few and abnormally looking (16). Genomic screening revealed novel mutations in the *DSG1* gene, consistent with a mild form of SAM syndrome (severe dermatitis, allergy and metabolic wasting) caused by desmoglein deficiency (17). Another example concerns the rare disorder *keratosis linearis, ichthyosis congenita with keratoderma (KLICK)*, which ultrastructurally exhibits massively enlarged keratohyalin granules (18). KLICK was eventually shown to be caused by recessive muta-

tions in the regulatory elements of the *POMP* gene interfering with the proteasome degradation of numerous epidermal proteins (19).

Although EM is invaluable in many studies of ichthyosis, it is a tedious and costly method only available in certain laboratories. As an alternative, immunofluorescence (IF) analysis can be used, for example, for detecting cytoskeletal abnormalities in patients with ichthyosis with confetti (20) or for experimental studies of cultured cells from patients with EI (21). Regarding the latter, Fig. S2<sup>2</sup> shows IF stainings of keratin 10 in differentiated keratinocytes from a patient with *KRT10* mutation before and after *in vitro* exposure to

heat. Clearly, heat stress causes aggregation of keratin filaments to a much higher extent than in healthy control cells (22). However, although the number of cellular aggregates was diminished by pre-treatment with a molecular chaperon designed to stabilize protein polymers (21), any extrapolation to the *in vivo* situation demands circumspection because the efficacy of topical chaperon was disappointing in a recent study of epidermolysis bullosa simplex, another keratinopathic disorder (23).

## BIOPHYSICAL PROPERTIES OF STRATUM CORNEUM IN RELATION TO ITS BARRIER FUNCTION

Invasive techniques are not always required for obtaining *in vivo* information about SC. By simply applying an evaporimeter and a flat glass electrode to the intact skin, measurement of TEWL, skin hydration (capacitance) and surface pH is possible. This low-tech approach is useful in both healthy and diseased skin; for instance, when studying the effects of various drugs and noxious agents potentially affecting the skin barrier (24, 25). Another finding from these studies is that TEWL is elevated in untreated ARCI skin and increases further after efficient treatment with topical keratolytics (26). While this might inadvertently enhance the pathomechanism of ichthyosis, remaining amounts of SC seems nearly always to be sufficient for preventing any harmful losses of water or influx of toxic substances via the skin.

However, when SC is mechanically removed *in toto* down to the glistening layer of epidermis, TEWL will increase dramatically (27). For obvious reasons, a concurrent increase in pH from ~5 on the skin surface to 7.4 in viable epidermis must then also occur, although details of this event for long remained unexplored (28). Fig. S3<sup>2</sup> shows that, soon after a complete removal of SC, pH and TEWL will start to decrease again, reaching normal surface values within 5–7 days, approximately one week before the full restoration of SC (28). Indeed, pH appears to normalize more quickly than TEWL, possibly reflecting its master role during barrier repair.

The importance of pH for SC homeostasis has also been highlighted by the discovery of a sigmoidal pH gradient over human SC, with its steepest slope occurring midway between stratum granulosum and the skin surface (28). This gradient, first demonstrated by repeated monitoring of pH in the course of >100 tape strippings, has since been confirmed using more sophisticated techniques in both human and mouse skin (29).

Interestingly, the pH gradient in SC looks quite different in *I. vulgaris* and XRI (30); in the former a shift towards less acidic values is observed, whereas the opposite is true for XRI (Fig. 2). The proposed explanation for this difference is a paucity of acidic break-down products of filaggrin (e.g. urocanic acid) in *I. vulgaris* and an accumulation of acidic  $\text{CSO}_4$  in XRI (30). Incidentally,  $\text{CSO}_4$  is a fascinating molecule, acting both as an inhibitor of SC desquamation (31) and as a signalling molecule during keratinocyte maturation (32, 33). In fact, a deficiency of  $\text{CSO}_4$  in epidermis due to recessive *SULT2B1* mutations may also cause ichthyosis (34).

The key components contributing to the pH gradient in normal SC appear to be urocanic acid, free fatty acids and sodium-hydrogen exchanger -1 (NHE-1), all accumulating in acidic microdomains near the skin surface (35). Clearly, a reduction of approximately 2 pH units over a distance of only 10–20  $\mu\text{m}$  (the normal thickness of SC) is biologically huge, and probably affects both lipid organization and protein structure at different depths of SC. Indeed, this makes treatment with pH-adjusting creams an intriguing option for some disorders of cornification (35–37). Examples of two pH-dependent enzymes operating in SC are kallikrein 5 and 7, the principal proteases involved in corneodesmosome degradation

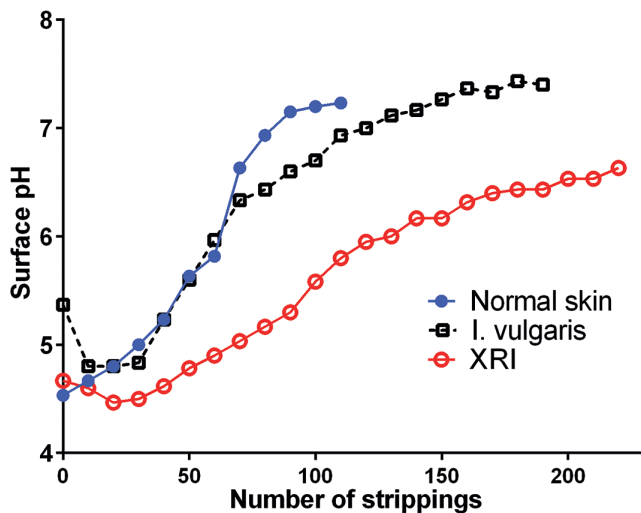
and desquamation (38). Besides pH, the activity of these enzymes depends on the amount of endogenous inhibitors, one of which is LEKTI (39). A genetic deficiency of LEKTI, as in Netherton syndrome (NS; *Ichthyosis circumflexa*), accelerates desquamation and reduces SC thickness to almost nil, hence dramatically increasing TEWL (39, 40). Ongoing clinical trials with topical application of synthetic inhibitors may lead to new treatments for NS and possibly atopic dermatitis, which is frequently associated with a secondary deficiency of LEKTI (41). Hypothetically, by modulating desquamation in the opposite direction, e.g. by blocking LEKTI, it might be possible to *increase* desquamation in some hyperkeratotic conditions, such as HI and EI, known to be associated with decreased secretion of proteolytic enzymes from the lamellar bodies (42, 43).

## BARRIER REPAIR AND GENOMIC RESPONSES

Considering the many different aetiologies of ichthyosis, it is not far-fetched to assume that homeostatic responses in epidermis will differ depending on the genotype and the extent of barrier insufficiency it causes. One way of testing this hypothesis is to study the global mRNA expression in epidermis, using microarray analysis of transcriptomes extracted from tissue biopsies and searching for differently expressed genes (DEGs) in ichthyosis compared with normal skin.

In such a recent study, microarrays consisting of 22,000 genes were applied to pooled skin extracts from healthy controls and untreated patients with either XRI or *I. vulgaris* due to mono- or bi-allelic *FLG* mutations (44, 45). While patients with XRI showed only 27 DEGs, patients with *I. vulgaris* showed up to 120 times as many DEGs (Fig. S4<sup>2</sup>). Speculatively, the low number of DEGs in XRI is due to  $\text{CSO}_4$ -induced hyperkeratosis reducing the need for more active barrier repair (46, 47). In *I. vulgaris*, since no “silent” generation of hyperkeratosis occurs, a chronic repair process takes place that might explain the abundance of DEGs. This hypothesis gains support from our gene ontology and qPCR analyses, showing activation of numerous genes involved in inflammation, lipid metabolism and hyperproliferation; the response is particularly evident in patients with biallelic *FLG* mutations who are also notoriously prone to develop eczema (24, 44).

When skin samples from patients with ARCI with *TGMI* mutations were similarly investigated, a broad spectrum of 256 DEGs appeared; 25 involved in keratinization and cell mobility, 46 in immune response and 8 in acylCer biosynthesis, the last of which are also known as “ARCI genes” because of their involvement in the ARCI aetiology (48). Speculatively, a marked up-regulation of several ARCI genes reflects a positive feedback loop aimed at generating more omega-O-acylCer for barrier repair. However, in ARCI patients with truncating *TGMI*



**Fig. 2.** The pH gradients over stratum corneum in healthy controls and patients with X-linked ichthyosis (XRI) or ichthyosis vulgaris (*I. vulgaris*). Mean pH values revealed by tape-stripping ( $n = 10$ – $11$  males in each group). When adjusting for the higher number of strippings required to remove SC in *I. vulgaris* (and XRI), the pH gradient will in the former case be shifted to the left compared to normal skin. (modified from refs. 28 and 30 with permission).

mutations such a response is probably useless; no matter how many lipid precursors are available in the granular cells the absence of transglutaminase-1 (TGm-1) will prevent a proper crosslinking of CE and CLE (49).

Further support for a concept of ARCI proteins operating in a feedback regulated pathway comes from our recent studies using IF staining combined with CellProfiler imaging, allowing semi-quantitative comparisons of the protein expression at different depths of epidermis (48). **Fig. 3** shows examples of results obtained in biopsies from 5 patients with *TGM1* mutations and 4 healthy controls. Clearly 2 of the studied proteins, CYP4F22 and CerS3, co-localize in the granular layer of epidermis in both patients and controls, but the protein expression is much higher in the patients, thus corroborating the microarray data. The co-localization of 2 other ARCI proteins, TGm-1 and SDR9C7, was studied in more detail in healthy control skin using *in situ* proximity ligation assay (*isPLA*), which generates a signal when 2 different proteins are at a distance of less than 30 nm from each other (50). While filaggrin did not produce any *isPLA* signals with either of the 2 ARCI proteins, together they produced a strong signal in stratum granulosum consistent with a close interaction between TGm-1 and SDR9C7 in a chain of events leading to a proper formation of CLE (51). TGm-1 has also been found to co-localize with 12R-LOX and eLOX-3 in stratum granulosum of normal epidermis, but not in ARCI epidermis with inactivating mutations in *NIPAL4* (encoding ichthyin) (52). This implies that ichthyin (a tentative transporter of  $Mg^{2+}$  (53)) is also essential for acylceramide synthesis, acting in close proximity to other ARCI proteins.

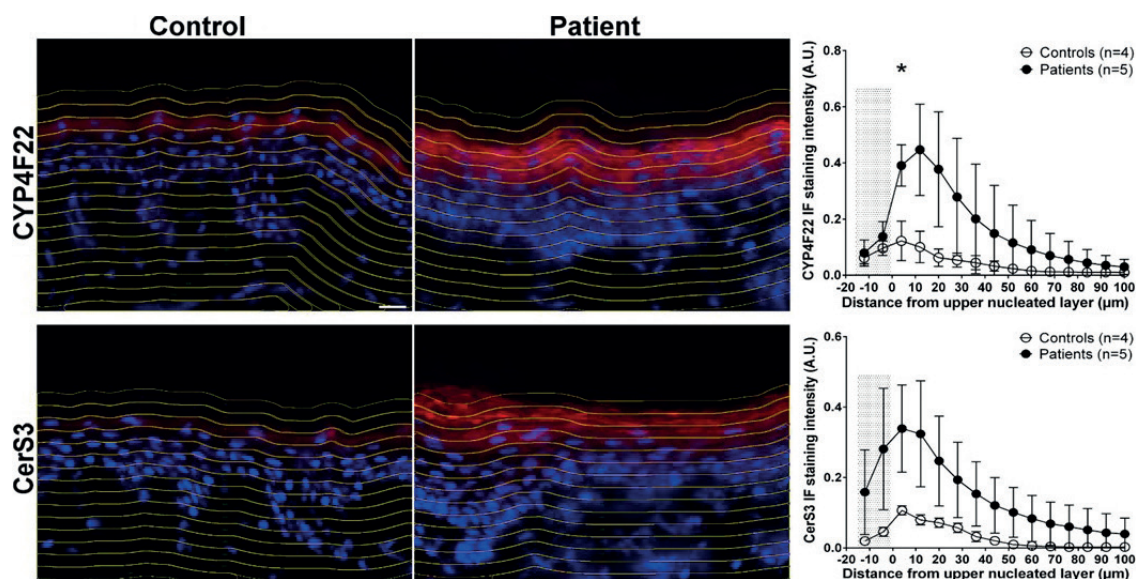
In addition to an increased expression of several wild-type ARCI genes, numerous other genes involved

in barrier repair, lipid biosynthesis, inflammation and anti-microbial peptides (AMPs) defence are also heavily upregulated in ARCI epidermis (48, 54–56). Incidentally, increased expression of AMPs might explain why microbial infections are rare in patients with lamellar ichthyosis despite a fissured and scaly skin. Analogously, psoriatic lesions express high levels of AMPs, albeit in this case on a background of much stronger immune and inflammatory reactions (57).

However, not all subtypes of ARCI exhibit a resilience against bacterial infections. For example, patients with HI and IPS often experience neonatal skin infections and septicaemia; in this case possibly related to a defective release of AMPs from the lamellar bodies (43). Furthermore, skin infections are frequent in EI with intrinsic defects in barrier repair, inter-corneocyte lipid deposition and AMP release (43, 58, 59), although in this case skin erosions and blistering are certainly a major contributing factor.

## BIOCHEMICAL AND GENETIC STUDIES OF EPIDERMIS

By simply scraping the skin surface with a sharp blade, samples of SC can be collected for analysis of, for example, CSO<sub>4</sub> (46), urocanic acid and natural moisturizing factors (NMFs) (60). Using slightly more invasive techniques, such as superficial shave biopsies, full-thickness samples of epidermis are obtainable without significant risk of scarring. After homogenization and extraction of such samples, sensitive analytical techniques, such as high-performance liquid chromatography (HPLC), allow quantitation of numerous endogenous compounds and drugs, such as vitamin A and retinoids. For example,



**Fig. 3.** Examples of immunofluorescence staining (left) and CellProfiler analysis (right) of the CYP4F22 and CERS3 proteins in patients with *TGM1* mutations versus healthy controls. The increased expression in patients' skin extends beyond the granular layer. The shaded area in the diagram correspond to stratum corneum (modified from ref. (48) with permission).

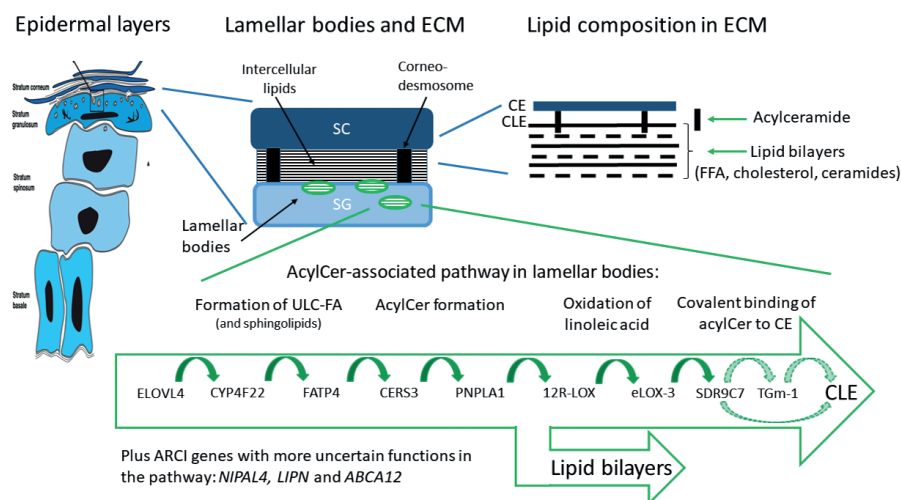
reduced concentrations of retinol (vitamin A<sub>1</sub>) were found in *I. vulgaris* and increased levels of 3,4-didehydroretinol (vitamin A<sub>2</sub>) in some types of hyperproliferative keratosis (61, 62), as yet without known significance. Although endogenous concentrations of all-*trans* retinoic acid in epidermis usually fall below the detection limit of the assay, therapeutic levels of isotretinoin and acitretin can be measured in shave biopsies (63, 64).

Using more sophisticated detection methods, such as ultra-performance liquid chromatography and mass-spectrum detection, the skin levels of fatty acids of different chain lengths, squalene and various types of ceramides (Cer) are quantifiable with high sensitivity and specificity (65–67). Indeed, the abnormal levels of various ceramides found in ARCI epidermis gave early clues to the existence of inborn errors of acylCer biosynthesis (68), which was later confirmed via gene hunting. **Fig. 4** summarizes our current understanding of lipid barrier formation in epidermis and the critical positioning of several ARCI proteins (for review see (4, 69, 70)). Subsequent to the enzymatic elongation of fatty acids (FA) by ELOVL4, the ultra-long chains (ULCFA) form amid-linkages with sphingosines, hence constituting Cer. This highly hydrophobic molecule undergoes a series of modifications, including a CYP4F22-mediated ω-hydroxylation of the FA moiety and subsequent transacylation with linoleic acid to form acylCer (71). The latter step, enhanced by PNPLA1, is essential for the formation of the lipid bilayers in SC. A significant fraction of acylCer undergoes further oxidation of the linoleate moiety, catalyzed by 12R-LOX and eLOX-3, and a subsequent covalent binding to CE (72). This final step in CLE formation was previously thought to be catalysed by TGM-1, analogous to the transacylation of involucrin. However, a recent report implicates an alternative pathway involving SDR9C7 (67). SDR9C7 is a dehydrogenase, that converts the oxidated linoleate molecule into a 13-ketone, a reactive moiety known for its non-enzymatic coupling to

protein (67). As a corollary, ARCI caused by SDR9C7 deficiency is characterized by absent CLEs on EM examination (67).

Interestingly, Crumrine et al. (70) recently proposed that virtually all the above-mentioned processes take place within the lamellar bodies, subsequently delivering preformed CLE scaffolds and lipid bilayers to the intercellular space via exocytosis. It was also suggested that some previously unexplained ultrastructural features in ARCI are actually caused by toxic levels of free FA accumulating in the keratinocytes owing to a downstream blockade in the acylCer pathway (70). As a possible extension to this “blockage theory”, our own findings of an upregulation of several ARCI proteins in the skin of patients with inactivating *TGM1* mutations (48) imply that lipoxygenated acylCer, instead of being converted to CLE by TGM-1, accumulates in the corneocytes as lipid aggregates or membranous. Speculatively, this might explain some of the EM characteristics of *TGM1*-associated ARCI (6). Conversely, more upstream blockages of acylCer biosynthesis, e.g. due to *CYP4F22* or *CERS3* mutations, might instead reduce the acylCer levels and thus impair the formation of both intercellular lipid bilayers and CLE. Although much remains to be clarified about this and the other pathogenic process in ARCI, there are already good arguments for distinguishing aetiologies related to inborn errors of the acylCer metabolism from other causes of ARCI; for example, by using prefixes, such as “lipodysgenic” or “lipid synthetic”, for this groups of disorders (48, 70).

Thanks to research mainly from France, Germany, Japan, Scandinavia, UK and the USA, it is now possible to genetically diagnose all forms of common and keratinopathic ichthyosis, and 85–90% of cases with ARCI (for review see (4)). With respect to the latter diagnosis, the leading causes of ARCI in Northern Europe are homozygous or compound heterozygous mutations in *TGM1* (30–35%), *ALOX12B* or *ALOXE3* (combined 15–20%) and *NIPAL4* (12–15%) (4, 73–76). Detailed discussions



**Fig. 4. Crucial components and biosynthetic steps in the formation of an epidermal lipid barrier.** Light green (hatched) arrows in the box indicate two alternative pathways in cornified lipid envelope (CLE) formation (modified from Am J Clin Derm (4) with permission). SC: stratum corneum, SG: stratum granulosum, ECM: extracellular matrix; CE: cornified envelope, FFA: free fatty acids, ULC-FA: ultra-long chain fatty acid, AcylCer: acyl ceramide, ELOVL4: ELOVL fatty acid elongase 4, CYP4F22: cytochrome P450 family 4 subfamily F member 22, FATP4: fatty acid transport protein 4, CERS3: ceramide synthase 3, PNPLA1: patatin-like phospholipase domain containing 1, 12R-LOX: arachidonate 12-lipoxygenase, 12R-type, eLOX-3: hydroperoxide isomerase ALOXE3, TGM-1: transglutaminase-1, NIPAL4: magnesium transporter NIPA4 (ichthyin), LIPN: lipase member N, SDR9C7: short-chain dehydrogenase/reductase family 9C member 7.

about the genetics of ichthyosis are available in 2 other papers (77, 78).

## CLINICAL EXAMINATION AND SERENDIPITY AS RESEARCH TOOLS

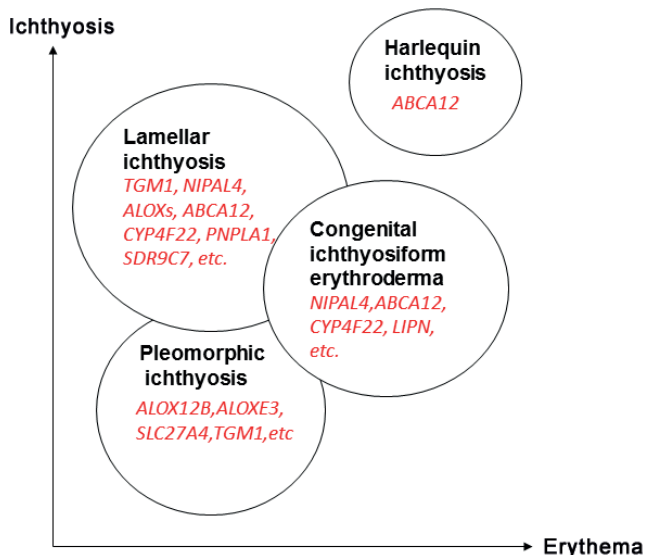
Patients with ichthyosis frequently exhibit skin signs and symptoms that may be difficult for the examining doctor to describe in a concise way or to score for severity grade, e.g. in relation to a scientific study. Characteristically, skin lesions may be generalized or only occur focally, and the intensity of scaling may range from mild to severe, with scales typically described as lamellar, collodion-like, cobblestone-like, brownish, fine and white, etc. Furthermore, a plethora of other symptoms occurs, such as xerosis, palmoplantar keratoderma, erythema, itch and pain, all with a variable degree of severity. Adding to this complexity, phenotypic fluctuations often occur over time, either spontaneously or as the result of treatment or environmental factors, e.g. work, climate and season of the year. No wonder then a consensus is still lacking about the best severity scoring system to use in clinical trials (for review see (79))

In clinical practice, however, less sophisticated scoring models may still be useful. For example, in a recent study of 132 patients with ARCI, separate scorings (0–4) of ichthyosis (IS) and erythema (ES) severity were made in 10 different body regions, followed by an area-adjusted summation of individual score values (4, 73, 80). When the IS and ES values recorded at age >1 year were plotted against one another in a diagram, the individual ratios roughly distributed into 4 partially overlapping circles seemingly corresponding to the major clinical subtypes identified at first examination, i.e. before the genetic re-

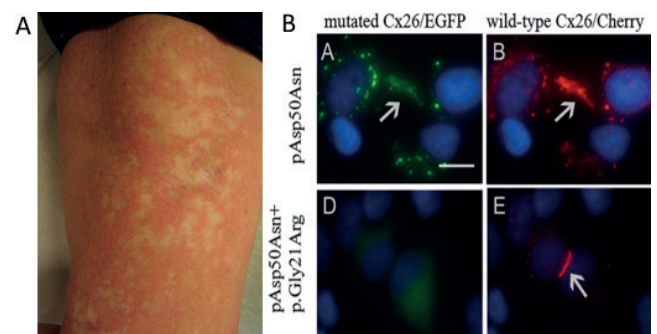
sults became known (Fig. 5). Unsurprisingly, harlequin ichthyosis (HI), the rarest and most severe subtype of ARCI due to truncating *ABCA12* mutations, shows the highest IS and ES values. Lamellar (LI) and erythrodermic ichthyosis (CIE), with more varied and partially overlapping phenotypes and genotypes, show high values of either IS or ES. The 4<sup>th</sup> entity, shows low values of both IS and ES, although most of the patients had severe skin symptoms at birth, healing spontaneously over a period of several weeks. This altering pattern is consistent with *pleomorphism*, “a condition in which an individual assumes a number of different forms during its life-cycle”. Accordingly, pleomorphic ichthyosis (PI) is a suggested new name for this subgroup of ARCI previously known as “non-LI/non-CIE” (80). It comprises several distinct conditions, such as self-improving collodion ichthyosis (mostly due to mild *ALOX12B* mutations), bathing-suit ichthyosis (due to temperature-sensitive *TGM1* mutations) and IPS (specifically caused by *SLC27A4* mutations) (73, 80, 81). (*Nb*: “syndrome” is probably a misnomer for IPS, because all extra-cutaneous symptoms appear to be secondary to the skin malfunction.)

While a crude classification of ARCI into 4 major subgroups may seem superfluous in an era of exact genetic diagnosing, it is still useful; for instance, when diagnosing ARCI without available genetic expertise or for teaching medical students how to distinguish between the various types of ichthyosis.

Another bonus of a detailed skin examination is the chance of making serendipitous findings. Fig. 6A illustrates such a case: a 45-year-old woman, diagnosed in childhood with keratitis, ichthyosis, deafness (KID) syndrome due to a recurrent mutation in *GJB2* (82). She started in her 20s to develop spots of normal-looking skin, which gradually grew in size and number, were histopathologically “non-lesional”. A subsequent sequencing of DNA from the healed spots revealed several



**Fig. 5.** Tentative correlation between ichthyosis and erythema severity 4 types of autosomal recessive congenital ichthyosis (ARCI) with partially overlapping phenotypes and culprit genes. (modified from refs. (4, 75) with permission).



**Fig. 6.** Patient with keratitis-ichthyosis-deafness (KID) syndrome showing spontaneous revertant *GJB2* mutation restoring the normal phenotype of keratinocytes. (A) Gradually appearing white spots in erythrodermic areas on the thigh, and (B) effects of the patient's somatic (silencing) mutation on an allele with germline *GJB2* mutation (EGFP) when transfected to HeLa cells together with wt-*GJB2* (Cherry). The blurred gap junctions (top panel), resembling the situation in lesional skin, are restored by the *de novo* somatic mutation (bottom panel) as in healed spots (modified from ref. (83) with permission).

*de novo* mutations restricted to the disease-causing *GJB2* allele. Co-transfection of germline and *de novo* (somatic) mutations together with *wt-GJB2* in HeLa cells showed that the *de novo* gene product remained intracellular, thus allowing an unopposed incorporation of wild-type connexin 26 into the gap-junctions (Fig. 6B) (83). Similar examples of spontaneous revertants in the skin have been described in epidermolysis bullosa (84), ichthyosis with confetti (85) and loricrin keratoderma (86). This makes drug enhancement of revertance (“natural gene therapy”) an interesting possibility for dominant negative genodermatoses (87, 88).

## NEW THERAPEUTIC DEVELOPMENTS

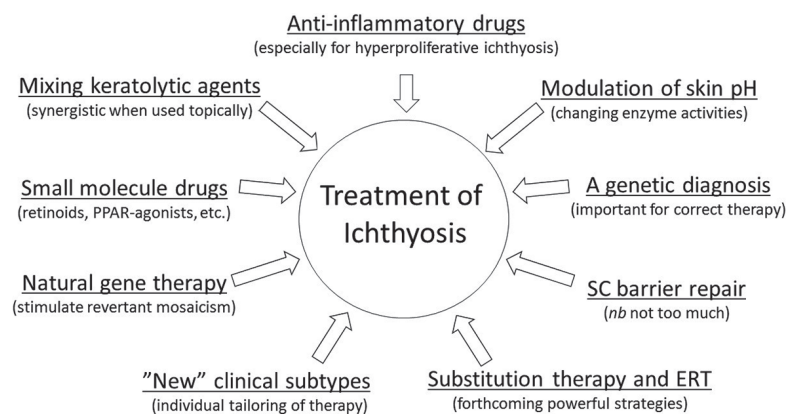
Besides emollients and keratolytic creams (2, 3, 26), retinoids remain mainstay therapy for moderate to severe forms of ichthyosis. Acitretin and isotretinoin are the preferred drugs for systemic use, with newcomers, such as alitretinoin, probably having a less favourable risk/benefit ratio (89), and retinoic acid metabolism blocking agents (RAMBAs), such as liarozole, not yet commercially available (90). Broadly speaking, vitamin A agonists have anti-keratinizing and keratolytic effects. However, because many retinoids bind to specific ligand-activated transcription factors and regulate the expression of numerous genes expressed in epidermis, more specific effects on ichthyosis pathogenesis are also to be expected. One example is the different outcome of retinoid treatment in patients with epidermolytic ichthyosis due to *KRT10* or *KRT1* mutations (91). Whereas the former patients respond quite well to low-dose retinoid therapy, consistent with a down-regulation of mutated *KRT10* (92), patients with *KRT1* mutations often get worse and develop more blisters during retinoid therapy (91). A proposed explanation is the ubiquitous down-regulation of *KRT2* by retinoids; this effect is harmless in both normal and *KRT10*-mutated epidermis, but deleterious in patients with *KRT1* mutations who depend on keratin 2 as a replacer of mutated keratin 1 during its dimerization with keratin 10 (93). Conversely, patients with the Siemens type of superficial ichthyosis, caused by keratin 2 mutations that interfere with its heterodimerization to keratin 9, are known to respond most favourably to retinoids (94).

Encouragingly, many new ideas for ichthyosis treatment are in the pipeline, targeting not only the causative mechanisms, but also secondary events, such as inflammation and hyperproliferation. Although gene therapy for skin diseases has not yet proved as successful as initially hoped, topical antisense therapy blocking the translation of mutated mRNA has shown promising results, at least in pachyonychia congenita,

a keratinopathic disorder mechanistically similar to epidermolytic ichthyosis (EI) (95). Moreover, disruption of mutated *KRT10* in EI keratinocytes using a transcription activator-like effector nuclease (TALEN) technology reverts the intermediate filament fragility *in vitro* (96). These and other approaches, such as CRISPR/Cas9 gene editing, aimed at correcting the underlying mutation *in situ*, holds promise for a more specific gene therapy for ichthyosis in the future (97, 98).

Substitution and replacement therapy are other interesting approaches. Since various types of ceramides can now be synthesized in large amounts, they are obvious candidates for testing topically in ARCI (99). Another, still preclinical, approach is to enhance the acylCer pathway via ligand stimulation of transcription factors, such as peroxisome proliferator activating receptors (PPARs) expressed in epidermis and known to affect the expression of many ARCI genes *in vitro* (100). Several PPAR agonists are already in use for diabetes and cardiovascular disease. However, for this hypothetical treatment to be effective in ARCI, all genes involved in CLE formation must remain at least marginally intact, implying that lipodysgenic ARCI due to truncating mutations will remain unresponsive. In this context, enzyme replacement therapy (ERT) with topically applied recombinant transglutaminase may become an attractive (but expensive) future option, especially for patients with *TGM1*-associated ARCI (101). Perhaps a combination of ERT and supplementation with synthetic ceramides would prove most versatile, although this approach remains to be studied.

As regards treatment of secondary pathogenic events, it is noteworthy that skin inflammation in ARCI has many similarities to psoriasis, making already approved biological therapies feasible to test in severe cases of ichthyosis (56). In the long term, the search for new therapies in ichthyosis should also focus on alternative ways to restore the skin barrier and to dampen excessive intrinsic responses, which often cause more harm than relief to the patient. Whether this goal is attainable through



**Fig. 7. Summary of ideas about future development of ichthyosis therapy.** ERT: enzyme replacement therapy.

gene technology and new biologics, or by specifically tailored molecules and substitution therapies, remains to be determined. **Fig. 7** gives a summary of these and other prospects for ichthyosis treatment.

## CONCLUSION

The skin is, both clinically and pre-clinically, a “research-friendly” organ. By combining a wide variety of investigative methods, ranging in complexity from simple *in vivo* measurements of TEWL and surface pH, to high-tech biochemical and genomic analyses of minimally invasive skin biopsies, or *in vitro* cultures of reconstituted skin, much information is attainable about the pathobiology of many skin diseases, not least ichthyosis.

Today, when almost 100 subtypes of ichthyosis have been characterized at both the genomic and ultrastructural level, an exact diagnosis early in life, a definite establishment of mode of inheritance, and an accurate genetic counselling should nearly always be feasible.

Though the treatment options have also evolved over the years, there is still a great need for new developments aimed at improving the patients’ quality of life. Through this research, new knowledge may also be gained about many other skin diseases with biological features similar to ichthyosis, such as eczema and psoriasis, which are also characterized by inflammation and a perturbed skin barrier.

## ACKNOWLEDGEMENTS

We thank our co-authors and the participating patients, health & laboratory staff, and funders for all their support in the presented studies.

*Conflicts of interest:* AV is the Chairman of the Society for Publication of *Acta Dermato-Venereologica*.

## REFERENCES

- Oji V, Tadani G, Akiyama M, Blanchet Bardon C, Bodemer C, Bourrat E, et al. Revised nomenclature and classification of inherited ichthyoses: results of the First Ichthyosis Consensus Conference in Soreze 2009. *J Am Acad Dermatol* 2010; 63: 607–641.
- Mazereeuw-Hautier J, Hernandez-Martin A, O’Toole EA, Bygum A, Amaro C, Aldwin M, et al. Management of congenital ichthyoses: European guidelines of care, part two. *Br J Dermatol* 2019; 180: 484–495.
- Mazereeuw-Hautier J, Vahlquist A, Traupe H, Bygum A, Amaro C, Aldwin M, et al. Management of congenital ichthyoses: European guidelines of care, part one. *Br J Dermatol* 2019; 180: 272–281.
- Vahlquist A, Fischer J, Törmä H. Inherited nonsyndromic ichthyoses: an update on pathophysiology, diagnosis and treatment. *Am J Clin Dermatol* 2018; 19: 51–66.
- Niemi KM, Kanerva L. Ichthyosis with laminated membrane structures. *Am J Dermatopathol* 1989; 11: 149–156.
- Niemi KM, Kanerva L, Kuokkanen K. Recessive ichthyosis congenita type II. *Arch Dermatol Res* 1991; 283: 211–218.
- Niemi KM, Kanerva L, Wahlgren CF, Ignatius J. Clinical, light and electron microscopic features of recessive ichthyosis congenita type III. *Arch Dermatol Res* 1992; 284: 259–265.
- Anton-Lamprecht I. Genetically induced abnormalities of epidermal differentiation and ultrastructure in ichthyoses and epidermolyses: pathogenesis, heterogeneity, fetal manifestation, and prenatal diagnosis. *J Invest Dermatol* 1983; 81: 149s–156s.
- Dahlqvist J, Klar J, Hausser I, Anton-Lamprecht I, Hellström Pigg M, Gedde-Dahl T, Jr, et al. Congenital ichthyosis: mutations in ichthyin are associated with specific structural abnormalities in the granular layer of epidermis. *J Med Genet* 2007; 44: 615–620.
- Ghadially R, Williams ML, Hou SY, Elias PM. Membrane structural abnormalities in the stratum corneum of the autosomal recessive ichthyoses. *J Invest Dermatol* 1992; 99: 755–763.
- Akiyama M, Sugiyama-Nakagiri Y, Sakai K, McMillan JR, Goto M, Arita K, et al. Mutations in lipid transporter ABCA12 in harlequin ichthyosis and functional recovery by corrective gene transfer. *J Clin Invest* 2005; 115: 1777–1784.
- Gånemo A, Pigg M, Virtanen M, Kukk T, Raudsepp H, Rossman-Ringdahl I, et al. Autosomal recessive congenital ichthyosis in Sweden and Estonia: clinical, genetic and ultrastructural findings in eighty-three patients. *Acta Derm Venereol* 2003; 83: 24–30.
- Bygum A, Westermark P, Brandrup F. Ichthyosis prematurity syndrome: a well-defined congenital ichthyosis subtype. *J Am Acad Dermatol* 2008; 59: S71–74.
- Klar J, Schweiger M, Zimmerman R, Zechner R, Li H, Törmä H, et al. Mutations in the fatty acid transport protein 4 gene cause the ichthyosis prematurity syndrome. *Am J Hum Genet* 2009; 85: 248–253.
- Virolainen E, Niemi KM, Gånemo A, Kere J, Vahlquist A, Saarialho-Kere U. Ultrastructural features resembling those of harlequin ichthyosis in patients with severe congenital ichthyosiform erythroderma. *Br J Dermatol* 2001; 145: 480–483.
- Schlipf NA, Vahlquist A, Teigen N, Virtanen M, Dragomir A, Fismen S, et al. Whole-exome sequencing identifies novel autosomal recessive DSG1 mutations associated with mild SAM syndrome. *Br J Dermatol* 2016; 174: 444–448.
- Samuelov L, Sarig O, Harmon RM, Rapaport D, Ishida-Yamamoto A, Isakov O, et al. Desmoglein 1 deficiency results in severe dermatitis, multiple allergies and metabolic wasting. *Nat Genet* 2013; 45: 1244–1248.
- Vahlquist A, Pontén F, Pettersson A. Keratosis linearis with ichthyosis congenita and sclerosing keratoderma (KLICK-syndrome): a rare, autosomal recessive disorder of keratohyaline formation? *Acta Derm Venereol* 1997; 77: 225–227.
- Dahlqvist J, Klar J, Tiwari N, Schuster J, Törmä H, Pujol R, et al. A single-nucleotide deletion in the POMP 5’ UTR causes a transcriptional switch and altered epidermal proteasome distribution in KLICK genodermatosis. *Am J Hum Genet* 2010; 86: 596–603.
- Diociaiuti A, Fortugno P, El Hachem M, Angelo C, Proto V, De Luca N, et al. Early immunopathological diagnosis of ichthyosis with confetti in two sporadic cases with new mutations in keratin 10. *Acta Derm Venereol* 2014; 94: 579–582.
- Chamcheu JC, Pihl-Lundin I, Mouyobo CE, Gester T, Virtanen M, Moustakas A, et al. Immortalized keratinocytes derived from patients with epidermolytic ichthyosis reproduce the disease phenotype: a useful in vitro model for testing new treatments. *Br J Dermatol* 2011; 164: 263–272.
- Chamcheu JC, Navsaria H, Pihl-Lundin I, Liovic M, Vahlquist A, Törmä H. Chemical chaperones protect epidermolysis bullosa simplex keratinocytes from heat stress-induced keratin aggregation: involvement of heat shock proteins and MAP kinases. *J Invest Dermatol* 2011; 131: 1684–1691.
- Spörrer M, Prochnicki A, Tolle RC, Nyström A, Esser PR, Homberg M, et al. Treatment of keratinocytes with 4-phenylbutyrate in epidermolysis bullosa: Lessons for therapies in keratin disorders. *EBioMedicine* 2019; 44: 502–515.
- Flohr C, England K, Radulovic S, McLean WH, Campbell LE, Barker J, et al. Filaggrin loss-of-function mutations are associated with early-onset eczema, eczema severity and transepidermal water loss at 3 months of age. *Br J Dermatol* 2010; 163: 1333–1336.
- Törmä H, Lindberg M, Berne B. Skin barrier disruption by sodium lauryl sulfate-exposure alters the expressions of



- involucrin, transglutaminase 1, profilaggrin, and kallikreins during the repair phase in human skin in vivo. *J Invest Dermatol* 2008; 128: 1212–1219.
26. Gånemo A, Virtanen M, Vahlquist A. Improved topical treatment of lamellar ichthyosis: a double-blind study of four different cream formulations. *Br J Dermatol* 1999; 141: 1027–1032.
  27. Frödin T, Skogh M. Measurement of transepidermal water loss using an evaporimeter to follow the restitution of the barrier layer of human epidermis after stripping the stratum corneum. *Acta Derm Venereol* 1984; 64: 537–540.
  28. Öhman H, Vahlquist A. In vivo studies concerning a pH gradient in human stratum corneum and upper epidermis. *Acta Derm Venereol* 1994; 74: 375–379.
  29. Schreml S, Meier RJ, Wolfbeis OS, Landthaler M, Szeimies RM, Babilas P. 2D luminescence imaging of pH in vivo. *Proc Natl Acad Sci U S A* 2011; 108: 2432–2437.
  30. Öhman H, Vahlquist A. The pH gradient over the stratum corneum differs in X-linked recessive and autosomal dominant ichthyosis: a clue to the molecular origin of the “acid skin mantle”? *J Invest Dermatol* 1998; 111: 674–677.
  31. Sato J, Denda M, Nakanishi J, Nomura J, Koyama J. Cholesterol sulfate inhibits proteases that are involved in desquamation of stratum corneum. *J Invest Dermatol* 1998; 111: 189–193.
  32. Kostarnoy AV, Gancheva PG, Lepenies B, Tukhvatulin AI, Dzharullaeva AS, Polyakov NB, et al. Receptor Mincle promotes skin allergies and is capable of recognizing cholesterol sulfate. *Proc Natl Acad Sci U S A* 2017; 114: E2758–E2765.
  33. Hanyu O, Nakae H, Miida T, Higashi Y, Fuda H, Endo M, et al. Cholesterol sulfate induces expression of the skin barrier protein filaggrin in normal human epidermal keratinocytes through induction of RORalpha. *Biochem Biophys Res Commun* 2012; 428: 99–104.
  34. Heinz L, Kim GJ, Marrakchi S, Christiansen J, Turki H, Rauschendorf MA, et al. Mutations in SULT2B1 cause autosomal-recessive congenital ichthyosis in humans. *Am J Hum Genet* 2017; 100: 926–939.
  35. Proksch E. pH in nature, humans and skin. *J Dermatol* 2018; 45: 1044–1052.
  36. Hachem JP, Roelandt T, Schurer N, Pu X, Fluhr J, Giddelo C, et al. Acute acidification of stratum corneum membrane domains using polyhydroxyl acids improves lipid processing and inhibits degradation of corneodesmosomes. *J Invest Dermatol* 2010; 130: 500–510.
  37. Ali SM, Yosipovitch G. Skin pH: from basic science to basic skin care. *Acta Derm Venereol* 2013; 93: 261–267.
  38. Brattsand M, Stefansson K, Lundh C, Haasum Y, Egelrud T. A proteolytic cascade of kallikreins in the stratum corneum. *J Invest Dermatol* 2005; 124: 198–203.
  39. Magert HJ, Standker L, Kreutzmann P, Zucht HD, Reinecke M, Sommerhoff CP, et al. LEKTI, a novel 15-domain type of human serine proteinase inhibitor. *J Biol Chem* 1999; 274: 21499–21502.
  40. Chavanas S, Bodemer C, Rochat A, Hamel-Teillac D, Ali M, Irvine AD, et al. Mutations in SPINK5, encoding a serine protease inhibitor, cause Netherton syndrome. *Nat Genet* 2000; 25: 141–142.
  41. Fortugno P, Furio L, Teson M, Berretti M, El Hachem M, Zambruno G, et al. The 420K LEKTI variant alters LEKTI proteolytic activation and results in protease deregulation: implications for atopic dermatitis. *Hum Mol Genet* 2012; 21: 4187–4200.
  42. Zhang L, Ferreyros M, Feng W, Hupe M, Crumrine DA, Chen J, et al. Defects in stratum corneum desquamation are the predominant effect of impaired ABCA12 function in a novel mouse model of harlequin ichthyosis. *PLoS One* 2016; 11: e0161465.
  43. Chan A, Godoy-Gijon E, Nuno-Gonzalez A, Crumrine D, Hupe M, Choi EH, et al. Cellular basis of secondary infections and impaired desquamation in certain inherited ichthyoses. *JAMA Dermatol* 2015; 151: 285–292.
  44. Winge MC, Hoppe T, Berne B, Vahlquist A, Nordenskjöld M, Bradley M, et al. Filaggrin genotype determines functional and molecular alterations in skin of patients with atopic dermatitis and ichthyosis vulgaris. *PLoS One* 2011; 6: e28254.
  45. Hoppe T, Winge MC, Bradley M, Nordenskjöld M, Vahlquist A, Berne B, et al. X-linked recessive ichthyosis: an impaired barrier function evokes limited gene responses before and after moisturizing treatments. *Br J Dermatol* 2012; 167: 514–522.
  46. Serizawa S, Osawa K, Togashi K, Yamamoto A, Ito M, Hamanaka S, et al. Relationship between cholesterol sulfate and intercellular cohesion of the stratum corneum: demonstration using a push-pull meter and an improved high-performance thin-layer chromatographic separation system of all major stratum corneum lipids. *J Invest Dermatol* 1992; 99: 232–236.
  47. Elias PM, Williams ML, Maloney ME, Bonifas JA, Brown BE, Grayson S, et al. Stratum corneum lipids in disorders of cornification. Steroid sulfatase and cholesterol sulfate in normal desquamation and the pathogenesis of recessive X-linked ichthyosis. *J Clin Invest* 1984; 74: 1414–1421.
  48. Zhang H, Ericsson M, Weström S, Vahlquist A, Virtanen M, Törmä H. Patients with congenital ichthyosis and TGM1 mutations overexpress other ARCI genes in the skin: Part of a barrier repair response? *Exp Dermatol* 2019; 28: 1164–1171.
  49. Schmidt R, Reichert U, Michel S, Shroot B, Bouclier M. Plasma membrane transglutaminase and cornified cell envelope competence in cultured human keratinocytes. *FEBS Lett* 1985; 186: 201–204.
  50. Söderberg O, Gullberg M, Jarvius M, Ridderstråle K, Leuchowius KJ, Jarvius J, et al. Direct observation of individual endogenous protein complexes in situ by proximity ligation. *Nat Methods* 2006; 3: 995–1000.
  51. Zhang H, Ericsson M, Virtanen M, Weström S, Wählby C, Vahlquist A, et al. Quantitative image analysis of protein expression and colocalization in skin sections. *Exp Dermatol* 2018; 27: 196–199.
  52. Li H, Pavez Lorié E, Fisher J, Vahlquist A, Törmä H. The expression of epidermal lipoxygenases and transglutaminase-1 is perturbed by NIPAL4 mutations: Indications of a common metabolic pathway essential for skin barrier homeostasis. *J Invest Dermatol* 2012; 132: 2368–2375.
  53. Honda Y, Kitamura T, Naganuma T, Abe T, Ohno Y, Sassa T, et al. Decreased skin barrier lipid acylceramide and differentiation-dependent gene expression in ichthyosis gene Nipal4-knockout mice. *J Invest Dermatol* 2018; 138: 741–749.
  54. Paller AS, Renert-Yuval Y, Suprun M, Esaki H, Oliva M, Huynh TN, et al. An IL-17-dominant immune profile is shared across the major orphan forms of ichthyosis. *J Allergy Clin Immunol* 2017; 139: 152–165.
  55. Haneda T, Imai Y, Uchiyama R, Jitsukawa O, Yamanishi K. Activation of molecular signatures for antimicrobial and innate defense responses in skin with transglutaminase 1 deficiency. *PLoS One* 2016; 11: e0159673.
  56. Malik K, He H, Huynh TN, Tran G, Mueller K, Doytcheva K, et al. Ichthyosis molecular fingerprinting shows profound TH17 skewing and a unique barrier genomic signature. *J Allergy Clin Immunol* 2019; 143: 604–618.
  57. Gallo RL, Murakami M, Ohtake T, Zaiou M. Biology and clinical relevance of naturally occurring antimicrobial peptides. *J Allergy Clin Immunol* 2002; 110: 823–831.
  58. Schmuth M, Yosipovitch G, Williams ML, Weber F, Hintner H, Ortiz-Urda S, et al. Pathogenesis of the permeability barrier abnormality in epidermolytic hyperkeratosis. *J Invest Dermatol* 2001; 117: 837–847.
  59. Schmuth M, Gruber R, Elias PM, Williams ML. Ichthyosis update: towards a function-driven model of pathogenesis of the disorders of cornification and the role of corneocyte proteins in these disorders. *Adv Dermatol* 2007; 23: 231–256.
  60. Takahashi M, Tezuka T. The content of free amino acids in the stratum corneum is increased in senile xerosis. *Arch Dermatol Res* 2004; 295: 448–452.
  61. Rollman O, Vahlquist A. Vitamin A in skin and serum – studies of acne vulgaris, atopic dermatitis, ichthyosis vulgaris and lichen planus. *Br J Dermatol* 1985; 113: 405–413.
  62. Vahlquist A, Lee JB, Michaelsson G. Darier's disease and vitamin A. Concentrations of retinoids in serum and epidermis of untreated patients. *Arch Dermatol* 1982; 118: 389–392.
  63. Rollman O, Vahlquist A. Retinoid concentrations in skin, serum and adipose tissue of patients treated with etretinate.

- Br J Dermatol 1983; 109: 439–447.
64. Rollman O, Vahlquist A. Oral isotretinoin (13-cis-retinoic acid) therapy in severe acne: drug and vitamin A concentrations in serum and skin. *J Invest Dermatol* 1986; 86: 384–389.
  65. Zheng Y, Yin H, Boeglin WE, Elias PM, Crumrine D, Beier DR, et al. Lipoxygenases mediate the effect of essential fatty acid in skin barrier formation: a proposed role in releasing omega-hydroxyceramide for construction of the corneocyte lipid envelope. *J Biol Chem* 2011; 286: 24046–24056.
  66. Ohno Y, Nakamichi S, Ohkuni A, Kamiyama N, Naoe A, Tsujimura H, et al. Essential role of the cytochrome P450 CYP4F22 in the production of acylceramide, the key lipid for skin permeability barrier formation. *Proc Natl Acad Sci U S A* 2015; 112: 7707–7712.
  67. Takeichi T, Hirabayashi T, Miyasaka Y, Kawamoto A, Okuno Y, Taguchi S, et al. SDR9C7 catalyzes critical dehydrogenation of acylceramides for skin barrier formation. *J Clin Invest* 2020; 130: 890–903.
  68. Paige DG, Morse-Fisher N, Harper JI. Quantification of stratum corneum ceramides and lipid envelope ceramides in the hereditary ichthyoses. *Br J Dermatol* 1994; 131: 23–27.
  69. Akiyama M. Corneocyte lipid envelope (CLE), the key structure for skin barrier function and ichthyosis pathogenesis. *J Dermatol Sci* 2017; 88: 3–9.
  70. Crumrine D, Khnykin D, Krieg P, Man MQ, Celli A, Mauro TM, et al. Mutations in recessive congenital ichthyoses illuminate the origin and functions of the corneocyte lipid envelope. *J Invest Dermatol* 2019; 139: 760–768.
  71. Miyamoto M, Itoh N, Sawai M, Sassa T, Kihara A. Severe skin permeability barrier dysfunction in knockout mice deficient in a fatty acid omega-hydroxylase crucial to acylceramide production. *J Invest Dermatol* 2020; 140: 319–326.e4.
  72. Krieg P, Furstenberger G. The role of lipoxygenases in epidermis. *Biochim Biophys Acta* 2014; 1841: 390–400.
  73. Hellström Pigg M, Bygum A, Gånemo A, Virtanen M, Brandrup F, Zimmer AD, et al. Spectrum of autosomal recessive congenital ichthyosis in Scandinavia: clinical characteristics and novel and recurrent mutations in 132 patients. *Acta Derm Venereol* 2016; 96: 932–937.
  74. Fischer J. Autosomal recessive congenital ichthyosis. *J Invest Dermatol* 2009; 129: 1319–1321.
  75. Eckl KM, de Juanes S, Kurtenbach J, Natebus M, Lugassy J, Oji V, et al. Molecular analysis of 250 patients with autosomal recessive congenital ichthyosis: evidence for mutation hotspots in ALOXE3 and allelic heterogeneity in ALOX12B. *J Invest Dermatol* 2009; 129: 1421–1428.
  76. Simpson JK, Martinez-Queipo M, Onoufriadis A, Tso S, Glass E, Liu L, et al. Genotype-phenotype correlation in a large English cohort of patients with autosomal recessive ichthyosis. *Br J Dermatol* 2019 Jun 6. [Epub ahead of print].
  77. Cortés H, Figueroa-González G, Reyes-Hernández O, Magana JJ, Leyva-García N, Carino-Calvo L, et al. Non-invasive methods for evaluation of skin manifestations in patients with ichthyosis. *Arch Dermatol Res* 2019 Oct 17. [Epub ahead of print].
  78. Uitto J, Youssefian L, Saeidian AH, Vahidnezhad H. Molecular genetics of keratinization disorders - what's new about ichthyosis. *Acta Derm Venereol* 2020; 100: 177–185.
  79. Fischer J, Bourrat E. Genetics of inherited ichthyoses and related diseases. *Acta Derm Venereol* 2020; 100: 186–196.
  80. Vahlquist A. Pleomorphic ichthyosis: proposed name for a heterogeneous group of congenital ichthyoses with phenotypic shifting and mild residual scaling. *Acta Derm Venereol* 2010; 90: 454–460.
  81. Vahlquist A, Bygum A, Gånemo A, Virtanen M, Hellström-Pigg M, Strauss G, et al. Genotypic and clinical spectrum of self-improving collodion ichthyosis: ALOX12B, ALOXE3, and TGM1 mutations in Scandinavian patients. *J Invest Dermatol* 2010; 130: 438–443.
  82. Bondeson ML, Nyström AM, Gunnarsson U, Vahlquist A. Connexin 26 (GJB2) mutations in two Swedish patients with atypical Vohwinkel (mitilating keratoderma plus deafness) and KID syndrome both extensively treated with acitretin. *Acta Derm Venereol* 2006; 86: 503–508.
  83. Gudmundsson S, Wilbe M, Ekvall S, Ameer A, Cahill N, Alexandrov LB, et al. Revertant mosaicism repairs skin lesions in a patient with keratitis-ichthyosis-deafness syndrome by second-site mutations in connexin 26. *Hum Mol Genet* 2017; 26: 1070–1077.
  84. Jonkman MF, Castellanos Nuijts M, van Essen AJ. Natural repair mechanisms in correcting pathogenic mutations in inherited skin disorders. *Clin Exp Dermatol* 2003; 28: 625–631.
  85. Choate KA, Lu Y, Zhou J, Choi M, Elias PM, Farhi A, et al. Mitotic recombination in patients with ichthyosis causes reversion of dominant mutations in KRT10. *Science* 2010; 330: 94–97.
  86. Suzuki S, Nomura T, Miyauchi T, Takeda M, Fujita Y, Nishie W, et al. Somatic recombination underlies frequent revertant mosaicism in lorincrin keratoderma. *Life Sci Alliance* 2019; 2. pii: e201800284.
  87. Pasmooij AM, Jonkman MF, Uitto J. Revertant mosaicism in heritable skin diseases: mechanisms of natural gene therapy. *Discov Med* 2012; 14: 167–179.
  88. Lim YH, Fisher JM, Choate KA. Revertant mosaicism in genodermatoses. *Cell Mol Life Sci* 2017; 74: 2229–2238.
  89. Gånemo A, Sommerlund M, Vahlquist A. Oral alitretinoin in congenital ichthyosis: a pilot study shows variable effects and a risk of central hypothyroidism. *Acta Derm Venereol* 2012; 92: 256–257.
  90. Vahlquist A, Blockhuys S, Steijlen P, van Rossem K, Didona B, Blanco D, et al. Oral liarozole in the treatment of patients with moderate/severe lamellar ichthyosis: results of a randomized, double-blind, multinational, placebo-controlled phase II/III trial. *Br J Dermatol* 2014; 170: 173–181.
  91. Virtanen M, Gedde-Dahl T, Jr, Mörk NJ, Leigh I, Bowden PE, Vahlquist A. Phenotypic/genotypic correlations in patients with epidermolytic hyperkeratosis and the effects of retinoid therapy on keratin expression. *Acta Derm Venereol* 2001; 81: 163–170.
  92. Li H, Törmä H. Retinoids reduce formation of keratin aggregates in heat-stressed immortalized keratinocytes from an epidermolytic ichthyosis patient with a KRT10 mutation. *Acta Derm Venereol* 2013; 93: 44–49.
  93. Törmä H. Regulation of keratin expression by retinoids. *Dermato-Endocrinology* 2011; 3: 136–140.
  94. Steijlen PM, van Dooren-Greebe RJ, Happle R, Van de Kerkhof PC. Ichthyosis bullosa of Siemens responds well to low-dosage oral retinoids. *Br J Dermatol* 1991; 125: 469–471.
  95. Leachman SA, Hickerson RP, Schwartz ME, Bullough EE, Hutcherson SL, Boucher KM, et al. First-in-human mutation-targeted siRNA phase Ib trial of an inherited skin disorder. *Mol Ther* 2010; 18: 442–446.
  96. March OP, Lettner T, Klausegger A, Ablinger M, Kocher T, Hainzl S, et al. Gene editing-mediated disruption of epidermolytic ichthyosis-associated KRT10 alleles restores filament stability in keratinocytes. *J Invest Dermatol* 2019; 139: 1699–1710 e1696.
  97. Abdul-Wahab A, Qasim W, McGrath JA. Gene therapies for inherited skin disorders. *Semin Cutan Med Surg* 2014; 33: 83–90.
  98. Lehmann J, Seebode C, Emmert S. Research on genodermatoses using novel genome-editing tools. *J Dtsch Dermatol Ges* 2017; 15: 783–789.
  99. Grond S, Eichmann TO, Dubrac S, Kolb D, Schmuth M, Fischer J, et al. PNPLA1 deficiency in mice and humans leads to a defect in the synthesis of omega-O-acylceramides. *J Invest Dermatol* 2017; 137: 394–402.
  100. Zhang H. Congenital Recessive Ichthyosis: Studies of gene expressions related to keratinocyte differentiation and skin barrier repair. Digital comprehensive summaries of Uppsala dissertations from the Faculty of Medicine, ISSN 1651-6206; 1541. Uppsala: Acta Universitatis Upsaliensis: Uppsala University, 2019: p. 58.
  101. Plank R, Yealland G, Miceli E, Lima Cunha D, Graff P, Thomforde S, et al. Transglutaminase 1 replacement therapy successfully mitigates the autosomal recessive congenital ichthyosis phenotype in full-thickness skin disease equivalents. *J Invest Dermatol* 2019; 139: 1191–1195.